

CASE REPORT

Open Access



# Canine panosteitis and preventive veterinary measures: insights from a case series

Luciano de Paulo Moreira<sup>1</sup>, Taís Fracalossi Zocatelli<sup>2</sup> and Camila Barbosa Amaral<sup>3\*</sup> 

## Abstract

**Background** Canine panosteitis is a self-limiting developmental orthopedic disease that, despite its name, causes bone marrow adipocyte degeneration and replacement by fibrous tissue. Pain-related lameness is the main clinical sign in young dogs from predisposed breeds such as German Shepherd. Etiology is unknown, and characteristic radiographic sign is increased medullary opacity of affected bone. This case series describes clinical course, radiographic findings, therapy and vaccination schemes adopted in four non-related German Shepherd dogs affected by panosteitis and attended sequentially at a private veterinary diagnostic center.

**Case presentation** Lameness was the unanimous clinical sign, accompanied by increased medullary radiopacity of the affected bone. Prescription medication included analgesic drugs and in two cases, nutraceuticals. Calcium supplement was prescribed for one of the dogs, but it was not administered by the owner. All dogs had full recovery from 2 to 14 days followed drug administration. Despite commonly described features, a high number of vaccine doses per patient, in the first months of age, were an intriguing observation, raising question about vaccination and the immune system influence in triggering such diseases in predisposed dogs.

**Conclusions** Although a common disease, panosteitis etiology remains undefined. Under this scenario and the presented cases, further research in order to revise vaccination protocols is advised for panosteitis predisposed breeds such as German Shepherd. Besides, local veterinary clinicians' unawareness of the disease was evident in many aspects and affected therapeutic prescription although not compromising patient recovery.

**Keywords** Panosteitis, German Shepherd dog, Radiography, Nutraceuticals, Vaccination, Immune system stimulation

## Background

Panosteitis is a self-limiting disease of unknown etiology that affects bone marrow of long bones (Demko and McLaughlin 2005; Kieves 2021; Tudor 2022). It was first described in 1951 in young German Shepherd dogs

(Lenehan et al 1985), and it was also referred to as juvenile osteomyelitis, enostosis, eosinophilic panosteitis and shifting leg lameness (Lenehan et al 1985; Fossum 2018; Tudor 2022).

Panosteitis affects dogs within the first year of age up to two years old in most of the cases. Large and giant breeds, such as German Shepherd, Doberman Pinscher, Golden and Labrador Retriever, Saint Bernard, Great Dane and Basset Hound, are more commonly impacted; in addition, male dogs are four times more frequently affected than females (Pollard and Phillips 2018; Fossum 2018; Kieves 2021; Tudor 2022). Thoracic limbs are more compromised than pelvic limbs (Kieves 2021), and most cited affected bones are humerus, femur, radius, ulna and tibia, varying on this order according to reference (Bergh 2015; Kieves 2021; Tilley et al. 2021).

\*Correspondence:

Camila Barbosa Amaral  
cbamaral@id.uff.br

<sup>1</sup> Departamento de Medicina Veterinária, Faculdade de Medicina Veterinária, Universidade Federal do Espírito Santo, Alegre, ES 29500-000, Brasil

<sup>2</sup> Focus Diagnóstico Veterinário - unidade Vitória, Vitória, ES 29090-720, Brasil

<sup>3</sup> Departamento de Patologia e Clínica Veterinária, Faculdade de Veterinária, Universidade Federal Fluminense, Av. Almirante Ary Parreiras, n.507, Vital Brazil, Niterói, RJ 24230-320, Brasil

Main clinical sign is acute lameness, usually without history of trauma, resolving in a few days with later recurrence to other bones (the “shifting” pattern) (Demko and McLaughlin 2005; Bergh 2015; Fossum 2018; Kieves 2021; Tilley et al. 2021; Tudor 2022). Pain on deep palpation of the affected long bone diaphysis is noticed on clinical examination (Bergh 2015; Fossum 2018; Millis and Janas 2021; Kieves 2021; Tilley et al. 2021). Despite its previous name, eosinophilia is rarely observed (Lenehan et al 1985; Tilley et al 2021). Microscopically, there is adipocyte degeneration (Bergh 2015; Kieves 2021), increased osteoblastic and fibroblastic activity in the diaphyseal endosteum and periosteum (Demko and McLaughlin 2005; Bergh 2015; Pollard and Phillips 2018; Kieves 2021; Tudor 2022) leading to medullary fibrosis (Demko and McLaughlin 2005; Kieves 2021; Tilley et al. 2021). Vascular proliferation and congestion centered around *foramen nutricium* (Demko and McLaughlin 2005; Kieves 2021) stimulate periosteal pain receptors (Demko and McLaughlin 2005).

Radiographs of affected long bones usually confirm panosteitis suspicion but also rule out differential diagnosis with similar clinical signs (Bergh 2015; Fossum 2018; Kieves 2021). Radiographic signs are increased intramedullary opacity which can be hazy and then evolve to well-defined, patchy radiopacities, with loss of trabecular bone pattern, usually around *foramen nutricium* (Lenehan et al 1985; Demko and McLaughlin 2005; Bergh 2015; Pollard and Phillips 2018; Kieves 2021; Ludewig and Kneissl 2022). Radiopacity may extend to the entire diaphysis (Pollard and Phillips 2018; Kieves 2021). The severity of radiographic lesions does not always correlate with clinical signs (Demko and McLaughlin 2005; Pollard and Phillips 2018; Kieves 2021).

This report aims to describe four cases of young German Shepherd dogs presenting clinical and radiographic signs of panosteitis referred to a diagnostic imaging center on the same trimester. Epidemiological, imaging and treatment aspects were evaluated in order to identify possible disease triggers and local veterinary clinicians’ awareness of the disease.

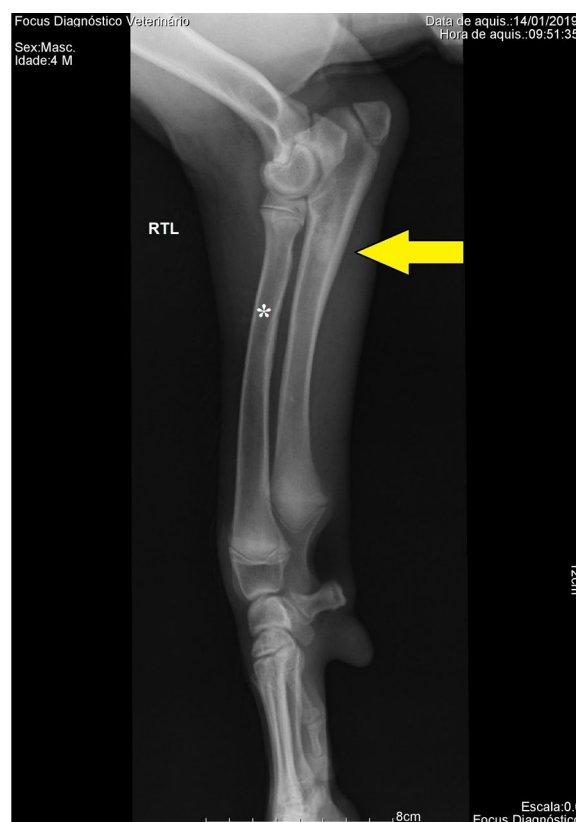**Case presentation**

Four dogs were presented at a diagnostic imaging center between January and April, 2019, in the city of Vila Velha, Espírito Santo (ES), Brazil. Epidemiological data are presented in Table 1.

All dogs presented lameness and pain on affected bones upon palpation. Dog #4 presented hyperthermia and dog #3 presented mild edema of the affected region. Clinical parameters were within normal range. Radiographic evaluation of the affected limb was requested on each case in order to elucidate lameness.

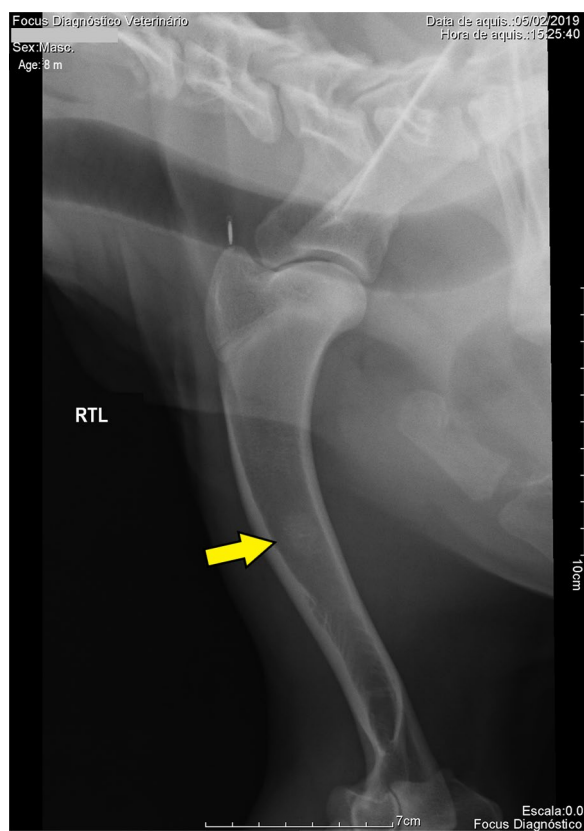
**Table 1** Epidemiological data concerning gender, breed, age (in months), weight and affected location of four dogs attended at a diagnostic imaging center, ES, Brazil

Dog	Gender	Age (m)	Weight (kg)	Breed	Affected bone
1	Male	4	21	German Shepherd	Right ulna
2	Male	8	30	German Shepherd	Right humerus
3	Female	8	29	German Shepherd	Right ulna
4	Male	7	29	German Shepherd	Right humerus



**Fig. 1** Radiography, right thoracic limb (RTL), lateral projection (dog #1): increased radiopacity compromising ulnar medullary cavity with prominent irregular radiopaque patches on proximal diaphysis and caudal cortical thickening (yellow arrow), suggesting panosteitis. Note oblique radiolucent line on radius cortical bone characterizing nutrient foramen (white asterisk)

Radiographs revealed medullary cavity increased radiopacity with ill-defined borders and loss of normal trabecular pattern in all affected bones: right ulna (dogs #1 and #3; Fig. 1) and right humerus (dogs #2 and #4; Fig. 2). Radiographic diagnosis suggested panosteitis in all four cases.



**Fig. 2** Radiography, right thoracic limb (RTL), lateral projection (dog #2): increased radiopacity compromising middle to distal humeral medullary cavity with cranial cortical thickening (yellow arrow) and trabecular pattern pronunciation (distal), suggesting panosteitis

Being all German Shepherd dogs from the same geographic region, parental investigation was performed. All animals were acquired from different dog kennels, and no kinship was found among records. No dog had history of falling or trauma before clinical signs reported by the owner. No previous complaint concerning limbs was reported.

No food supplement was taken by the dogs, although a calcium-based product was prescribed to dog #3.

Commercial food was the only option provided, following manufacturer’s instructions. All dogs presented body score 5/9, within breed and age normal limits.

Vaccination doses were registered (Table 2).

Therapeutic measures adopted by veterinary clinicians before radiographic evaluation aimed at pain relief, including nonsteroidal anti-inflammatory (NSAID) and analgesic drugs. Nutraceuticals referred as “articular regenerator” composed of glucosamine and chondroitin were also prescribed (Table 3). According to owners, lameness and local pain ceased from 2 to 14 days after drugs administration.

**Discussion**

Panosteitis is a disease studied over the last 70 years (Lenehan et al 1985). The German Shepherd is reported to be the most commonly affected breed in several studies (Bergh 2015; Igna et al 2016; Millis and Janas 2021; Kieves 2021; Tilley et al. 2021) and is considered predisposed to this disease (Gough and Thomas 2004). This apparent predisposition raises questions about the genetic basis of panosteitis (Tilley et al 2021) and its heritability, as observed in other developmental orthopedic diseases such as hypertrophic osteodystrophy (HOD) in Weimaraner puppies (Harrus et al 2002). Still nowadays, no study has demonstrated panosteitis genetic evidence in that breed or any other. No parental relationship was found between studied dogs in order to support genetic inheritance trait in this case series.

Panosteitis, considered to affect dogs exclusively, is characterized by increased, irregular radiopacity of affected long bone medullary cavity with cortical thickening and periosteal involvement (Lenehan et al 1985; Demko and McLaughlin 2005; Bergh 2015; Pollard and Phillips 2018; Kieves 2021; Ludewig and Kneissl 2022; Tudor 2022). This was observed in all studied cases, reinforcing constant and characteristic radiographic pattern of panosteitis. Cortical and periosteal involvement is absent and considered a differential radiographic feature from enostosis-like lesions (ELL) which occurs in equids,

**Table 2** Vaccination data (type of vaccine and number of doses) of four dogs attended at a diagnostic imaging center

Animal	Number of Doses					
	CV8	CV10	Rabies	Giardia	KCV	Leishmaniasis vaccine
1	0	3	1	0	0	3
2	0	3	1	1	1	0
3	0	3	1	0	1	0
4	3	0	1	0	0	0

CV8: core vaccine 8 (CDV, CAV1, CAV2, CPV2, CPiV, CCoV, *Leptospira canicola* and *icterohaemorrhagiae*); core vaccine 10 (CV8 plus *Leptospira grippityphosa* and *pomona*); KCV: kennel cough vaccine (against canine infectious respiratory disease complex; CIRDC)

**Table 3** Therapeutic oral drugs prescribed before and maintained after radiographic diagnosis of four dogs with panosteitis attended to at a diagnostic imaging center

Animal	NSAID	Analgesic	Articular supplement
1	Carprofen (2.2 mg/kg/BID/7 days)	Tramadol (2.0 mg/kg/TID/7 days)	0
2	Meloxicam (0.5 mg/kg/BID/7 days)	Dipyrone (25 mg/kg/BID/5 days)	0
3	Meloxicam (0.5 mg/kg/BID/7 days)	Dipyrone (25 mg/kg/BID/3 days)	Pro Cart® 25 <sup>a</sup>
4	Meloxicam (0.2 mg/kg/BID/15 days)	Tramadol (2.0 mg/kg/TID/5 days)	Condroton® 500 <sup>b</sup>

<sup>a</sup> Agener União Saúde Animal<sup>b</sup> Vetrnil<sup>a, b</sup> According to manufacturer's recommendations

mostly adult and old horses (O'Neill and Bladon 2011). Only two reported cases of "suspected" panosteitis, other than canine, were found: a 6-month-old camel (Levine et al 2007) and a 1.5-month-old calf (Sato et al. 2015). Both cases presented increased medullary opacity, cortical thickening and periosteal reaction on radiographs and were confirmed histopathologically by core biopsy.

Dogs are commonly affected between 5 and 18 months of age (Lenehan et al 1985; Demko and McLaughlin 2005; Bergh 2015; Pollard and Phillips 2018; Fossum 2018; Kieves 2021; Tilley et al 2021; Tudor 2022). In this case series, the mean age of clinical signs was 6.75 months, with one dog presenting signs a little earlier than that. This can be related to disease inner factors or to owner's keen attention. Despite the small sample, males were more affected than females, as previously described (Lenehan et al 1985; Demko and McLaughlin 2005; Bergh 2015; Pollard and Phillips 2018; Fossum 2018; Kieves 2021; Tilley et al 2021). Studies may present different results regarding the most affected bones; however, thoracic limbs are generally regarded to be more commonly affected, with humerus as the most cited bone (Demko and McLaughlin 2005; Millis and Janas 2021; Kieves 2021; Tudor 2022), similar to presented cases. Ulna, as a thoracic limb bone, agrees with statements regarding panosteitis most affected limbs.

Trauma can cause lameness, an ordinary clinical sign concerning developmental orthopedic diseases (Demko and McLaughlin 2005; Millis and Janas 2021; Kieves 2021). Synchronicity between traumatic events and panosteitis clinical expression can mask lameness origin and delay diagnostic confirmation (Demko and McLaughlin 2005; Bergh 2015; Millis and Janas 2021; Kieves 2021). Among presented cases, no dog had history of previous trauma, increasing the need for radiographic evaluation in order to elucidate diagnostic suspicion.

Pain-related lameness is a very common clinical sign in a plethora of orthopedics disease (Demko and McLaughlin 2005; Bergh 2015; Millis and Janas 2021; Kieves 2021) and was identified in all studied cases. Panosteitis

differential diagnosis includes osteochondritis dissecans, hip dysplasia, hypertrophic osteodystrophy, fragmented coronoid process and ununited anconeal process (Demko and McLaughlin 2005; Bergh 2015; Fossum 2018; Kieves 2021; Tilley et al 2021; Tudor 2022). However, in panosteitis, limb palpation plays an important role at clinical examination, especially in cases involving middle diaphysis, a not so common feature of other orthopedic diseases (Bergh 2015; Fossum 2018; Millis and Janas 2021; Kieves 2021; Tudor 2022).

No evaluated dog was considered to be overweight. Overfed large breed puppies are known to be at a higher risk of osteoarthritis (Greco 2014; Kim and Wakshlag 2023), an important condition related to orthopedic disease in predisposed breeds such as German Shepherd.

Mineral requirements differ between large and small breed puppies. Excessive calcium supplementation resulted in bone defects, such as panosteitis, and depressed growth in Great Dane puppies (Greco 2014; Beynen 2021), a large breed also cited to be affected by panosteitis (Lenehan et al 1985; Demko and McLaughlin 2005; Kieves 2021). Misguided use of puppy milk replacers in German Shepherd puppies was implicated in a higher risk of excessive calcium intake that could influence developing skeletal diseases such as panosteitis (Corbee et al 2012) since canine milk differs from replacers such as bovine and caprine milk regarding protein profile, fatty acids and minerals composition (Zhang et al 2022). Controlled skeletal growth is associated with normal development in large and giant breed dogs, and calcium supplements should not be prescribed focusing on bone growth (Greco 2014; Kim and Wakshlag 2023). In presented cases, no dog received calcium-based supplement; however, it was prescribed to dog #3, but not administrated by the owner. This fact shows how calcium intake still plays an erratic role in large breed dogs growth and developmental orthopedic disease among some veterinary clinicians and breeders.

Panosteitis was associated with annual vaccination reinforcement in German Shepherd dogs from a kennel

(Weir et al 1994). Live virus vaccines were reported to induce hypertrophic osteodystrophy (HOD) on a litter of Weimaraner puppies. Vaccines, among other environmental factors, were supposed to trigger clinical manifestation of HOD in genetically susceptible animals (Harrus et al 2002; Dodds 2021). Many vaccination adverse reactions are reported: hypersensitivity and allergic events, feline injection site sarcoma (FISS) and association to autoimmune diseases in combination with genetics and environmental factors (Gershwin 2018; Dodds 2021; Yoshida et al. 2021). Despite these observations, a high number of vaccine doses received by each studied dog before one year of age were noticed, reflecting local clinical management. Some of these vaccines, such as Giardia, are not recommended by WSAVA guidelines due to insufficient scientific evidence and are available only in Latin America. Leishmaniasis vaccine is recommended only to dogs at risk of infection in endemic areas, such as Brazil, but must not be taken as single preventive measure. Inclusion of canine coronavirus in core vaccines is no longer recommended due to insufficient scientific evidence to justify their use (Day et al 2020). Interestingly, dog #1 received the highest number of vaccine doses and was the youngest to present clinical signs, precociously compared to epidemiological data. A high number of vaccine shots trigger immune system response against too many antigens in a short time interval, increasing adverse effects probability (Dodds 2021). Although not proven, this could result in specific cytokines secretion which could contribute to panosteitis cellular events in predisposed dogs. More studies are needed in order to prove the relationship between vaccination, immune system stimulation and developmental orthopedic diseases such as panosteitis and HOD, especially in predisposed breeds such as German Shepherd.

In a study to determine clinical decision threshold, in a hypothetical panosteitis case, interviewed veterinary clinicians were asked to decide whether to recommend limb radiography or to prescribe NSAID for clinical signs. Fifty-eight percent chose to recommend radiography before treating. It demonstrated concern with establishing a diagnosis before treating a clinical suspicion and ruling out conditions with higher risk than self-limiting panosteitis (Guevara et al 2019). In a survey of panosteitis incidence, 65% of the cases were radiographically confirmed; the remaining was diagnosed based on clinical signs such as lameness and findings such as painful diaphysis at deep palpation (Igna et al 2016). Owner's financial restriction can impact veterinary diagnostic and treatment decisions (Guevara et al 2019) in developing countries such as Brazil. Despite that, radiography is a non-invasive, available diagnostic method with high cost-benefit ratio and can easily confirm panosteitis

suspicion. Hence, it is often recommended for diagnostic verdict and to eliminate differential diagnosis.

In the studied cases, it was noticed that no radiography request presented any clinical suspicion. All of them were concerned about elucidating lameness cause and only in two requests were pain at limb palpation cited. These observations may reflect local veterinary clinicians unawareness of the disease as well as low regional incidence. A Romanian retrospective study from 2000 to 2015 revealed that panosteitis diagnosis increases 375% from first to last year of study (Igna et al 2016). These findings may suggest the following: (1) European veterinary clinicians are more aware of the disease; (2) European owners pay more attention to their pets; and/or (3) a geographically increase in panosteitis clinical expression due to factors related to disease pathogenesis. In this presented report, four dogs were radiographically diagnosed at the same diagnostic imaging center in less than four months. This was not necessarily related to an increased awareness of the disease (since no medical request presented panosteitis as clinical suspicion). Instead, it can indicate professional commitments to diagnostic modalities instead of relying on a presumptive diagnosis and adopting a clinical sign-based treatment, similar to previous findings (Guevara et al 2019).

Evaluating therapeutic prescription, basically all clinicians prescribed analgesics such as opioids and NSAID, in agreement with the literature (Demko and McLaughlin 2005; Bergh 2015; Fossum 2018; Kieves 2021; Tilley et al. 2021) even without disease confirmation. This decision demonstrates commitment with patient welfare more than disease knowledge itself. Supplement containing glucosamine and chondroitin, nutraceuticals known as chondroprotectants (Johnson et al. 2020; Mosley et al. 2022), was prescribed. These components are related to chondrocytes and synoviocytes metabolism, synovial fluid and cartilage matrix improvement in osteoarthritis (Johnson et al. 2020; Mosley et al. 2022). Hence, based on panosteitis histopathological findings, these components are not supposed to have any therapeutic effect in panosteitis cases to justify their use. Once again, such prescription attests lack of knowledge by many veterinary clinicians about panosteitis physiopathology.

Panosteitis is a self-limiting disease and dogs often return to their normal activities as soon as pain ceases that can last from a few days to over a month. Disease recurrence is common until complete bone growth (around 1 year), sometimes extending to 2 years (Demko and McLaughlin 2005; Bergh 2015; Fossum 2018; Kieves 2021; Tilley et al. 2021; Tudor 2022). In this case series, all dogs returned to their daily activities from 2 to 14 days, even under analgesic medication. This is within expected time range but is

considered a rapid recovery when compared to other pediatric orthopedic diseases. Dog #3, the only female, still presented pain-related lameness after 7-day NSAID therapy. In this occasion, articular supplement was prescribed and improvement with complete recovery was observed after 7 days more. Despite this fact, it is not possible to ensure if clinical signs complete remission was attributed to articular supplement use or was just disease natural course. Another interesting observation is that no dog had disease recurrence and all of them had finished their vaccination protocols; hence, none of them was vaccinated after panosteitis episode. This temporal association may reinforce “cytokine storm” and immune system influence hypothesis in triggering panosteitis in predisposed dogs.

## Conclusions

Canine panosteitis, although a common developmental orthopedic disease, is still not included in differential diagnosis list in lamming young dogs in some locations, and its unknown etiology often leads to incorrect therapeutic prescription. Although not proven a trigger factor, caution is recommended regarding pediatric vaccination, vaccines doses intervals and immune system stimulation in panosteitis predisposed breeds.

## Abbreviations

ES	Espírito Santo
CV8	Core vaccine 8
CDV	Canine distemper virus
CAV1/CAV2	Canine adenovirus type 1 / 2
CPV2	Canine parvovirus type 2
CPIV	Canine parainfluenza virus
CCoV	Canine coronavirus
CV10	Core vaccine 10 (CV8 plus <i>Leptospira grippityphosa</i> and <i>pomona</i> )
KCV	Kennel cough vaccine
CIRDC	Canine infectious respiratory disease complex
NSAID	Nonsteroidal anti-inflammatory drug
BID	Bis in die (twice a day)
TID	Ter in die (three times a day)
HOD	Hypertrophic osteodystrophy
ELL	Enostosis-like lesions
FISS	Feline injection site sarcoma
WSAVA	World Small Animal Veterinary Association
RTL	Right thoracic limb

## Acknowledgements

All radiographic examinations were performed at Focus Diagnóstico Veterinário—Vila Velha unit (29102-020) and evaluated by the same radiologist (TFZ) in agreement with Diagnostic Imaging professor (CBA).

## Author contributions

LPM was involved in conceptualization, data curation, formal analysis, investigation, visualization and writing—original draft. TFZ was involved in conceptualization, data curation, formal analysis, investigation and writing—original draft. CBA was involved in conceptualization, formal analysis, methodology, project administration, supervision, visualization, writing—original draft and writing—review and editing. All authors read and approved the final manuscript.

## Funding

This study was not supported by any funding.

## Availability of data and materials

Not applicable.

## Declarations

### Ethics approval and consent to participate

All applicable international, national and/or institutional guidelines for the care and use of animals were followed. All procedures followed Veterinary Medicine Federal Council of Brazil guidelines and were performed with owners' previous consent. Informed consent was obtained from all individual participants (dog owners) included in the study.

### Consent for publication

Consent for publication was obtained for every individual animal's data included in the study.

### Competing Interests

The authors declare that they have no competing interest.

Received: 5 September 2023 Accepted: 11 December 2023

Published online: 19 December 2023

## References

- Bergh MS (2015) Panosteitis. In: Clinician's brief – Orthop Rehab focus 13:10–11. 2015. Accessed 28 Apr 2020 from <https://www.cliniciansbrief.com/article/panosteitis>.
- Beynen AC (2021) Diet and enostosis in dogs [Voeding en enostosis bij de hond]. *Dier-En-Arts* 10:245–2478
- Corbee RJ, Tryfonidou MA, Beckers IP, Hazewinkel HAW (2012) Composition and use of puppy milk replacers in German Shepherd puppies in the Netherlands. *J Anim Physiol Anim Nutr* 96:395–402. <https://doi.org/10.1111/j.1439-0396.2011.01153.x>
- Day MJ, Crawford C, Marcondes M, Squires RA (2020) Recommendations on vaccination for Latin American small animal practitioners: a report of the WSAVA Vaccination Guidelines Group. *J Small Anim Pract* 61:E1–E35. <https://doi.org/10.1111/jsap.13125>
- Demko J, McLaughlin R (2005) Developmental orthopedic disease. *Vet Clin North Am Small Anim Pract* 35:1111–1135. <https://doi.org/10.1016/j.cvsm.2005.05.002>
- Dodds WJ (2021) Early life vaccination of companion animal pets. *Vaccines* 9:92. <https://doi.org/10.3390/vaccines9020092>
- Fossum TW (2018) Other diseases of bones and joints. In: Fossum TW (ed) *Small animal surgery*. Elsevier, St. Louis, pp 1391–1410
- Gershwin LJ (2018) Adverse reactions to vaccination: from anaphylaxis to autoimmunity. *Vet Clin North Am Small Anim Pract* 48:279–290. <https://doi.org/10.1016/j.cvsm.2017.10.005>
- Gough A, Thomas A (2004) Part I dogs. In: Gough A, Thomas A (eds) *Breed predispositions to disease in dogs and cats*. Blackwell Publishing, Yowa, pp 11–160
- Greco D (2014) Pediatric Nutrition. *Vet Clin North Am Small Anim Pract* 44:265–273. <https://doi.org/10.1016/j.cvsm.2013.11.001>
- Guevara NT, Hofmeister E, Ebell M, Locatelli I (2019) Study to determine clinical decision thresholds in small animal veterinary practice. *Vet Rec* 185:170–180. <https://doi.org/10.1136/vr.104596>
- Harrus S, Waner T, Aizenberg I, Safra N, Mosenco A, Radoshitzky M, Bark H (2002) Development of hypertrophic osteodystrophy and antibody response in a litter of vaccinated Weimaraner puppies. *J Small Anim Pract* 43:27–31. <https://doi.org/10.1111/j.1748-5827.2002.tb00006.x>
- Igna C, Dascălu R, Bumb D, Sicoe B, Schüzler L (2016) The incidence of panosteitis in dogs admitted in surgery clinic of the faculty veterinary medicine Timisoara - retrospective study (2000–2015). *Sci Works, Series C Vet Med* 62:69–72

- Johnson KA, Lee AH, Swanson KS (2020) Nutrition and nutraceuticals in the changing management of osteoarthritis for dogs and cats. *J Am Vet Med Assoc* 256:1335–1341. <https://doi.org/10.2460/javma.256.12.1335>
- Kieves NR (2021) Juvenile disease processes affecting the forelimb in canines. *Vet Clin North Am Small Anim Pract* 51:365–382. <https://doi.org/10.1016/j.cvs.2020.12.004>
- Kim HT, Wakshlag JJ (2023) Nutrition and theriogenology: a glimpse into nutrition and nutritional supplementation during gestation, lactation, weaning and breeding dogs and cats. *Vet Clin North Am Small Anim Pract* 53:1083–1098. <https://doi.org/10.1016/j.cvs.2023.05.003>
- Lenahan TM, van Sickle DC, Biery DN (1985) Canine panosteitis. In: Newton CD, Nunamaker MD (eds) *Textbook of small animal orthopedics*. J.B. Lippincott, Philadelphia, pp 597–601
- Levine DG, Smith JJ, Richardson DW, Brown V, Beech J, Habecker P, Adam E (2007) Suspected panosteitis in a camel. *J Am Vet Med Assoc* 231:437–441. <https://doi.org/10.2460/javma.231.3.437>
- Ludewig E, Kneissl S (2022) Wenn das Übel gut erkennbar ist, ist es schon zu spät - Röntgendiagnostik häufiger und seltener Wachstumsstörungen des Skeletts beim Hund. *LBH: 11. Leipziger Tierärztekongress Tagungsband 1:325–333*
- Millis D, Janas K (2021) Forelimb examination, lameness assessment, and kinetic and kinematic gait analysis. *Vet Clin North Am Small Anim Pract* 51:235–251. <https://doi.org/10.1016/j.cvs.2020.10.001>
- Mosley C, Edwards T, Romano L, Truchetti G, Dunbar L, Schiller T, Gibson T, Bruce C, Troncy E (2022) Proposed Canadian consensus guidelines on osteoarthritis treatment based on OA-COAST stages 1–4. *Front Vet Sci* 9:830098. <https://doi.org/10.3389/fvets.2022.830098>
- O'Neill HD, Bladon BM (2011) Retrospective study of scintigraphic and radiological findings in 21 cases of enostosis-like lesions in horses. *Vet Rec* 168:326. <https://doi.org/10.1136/vr.c6168>
- Pollard RE, Phillips KL (2018) Orthopedic diseases of young and growing dogs and cats. In: Thrall DE (ed) *Textbook of veterinary diagnostic radiology*. Elsevier, St. Louis, pp 347–365
- Sato R, Ito T, Suganuma T, Une Y, Kudo T, Kayanuma H, Kanai E, Suzuki T, Ochiai H, Enomoto N, Itoh S, Onda K, Wada Y (2015) Suspected panosteitis in a crossbred calf. *Can Vet J* 56:463–465
- Tilley LP, Smith FWK, Sleeper MM, Brainard BN (2021) Panosteitis. In: Tilley LP et al (eds) *Blackwell's five-minute veterinary consult: canine and feline*. John Wiley & Sons Inc, New Jersey, pp 1034–1035
- Tudor N (2022) Clinical and radiographic aspects of panosteitis in dogs [Aspecte clinice și radiografice în panosteita câinilor]. *Practica Veterinară*. ro 36:41–44
- Weir JAM, Yager JA, Caswell JL, Parker WM, Johnstone IB, Basrur PK, Emms C (1994) Familial cutaneous vasculopathy of German shepherds: clinical, genetic and preliminary pathological and immunological studies. *Can Vet J* 35:763–769
- Yoshida M, Mizukami K, Hisasue M, Imanishi I, Kurata K, Ochiai M, Itoh M, Nasukawa T, Uchiyama J, Tsujimoto H, Sakaguchi M (2021) Anaphylaxis after rabies vaccination for dogs in Japan. *J Vet Med Sci* 83:1202–1205. <https://doi.org/10.1292/jvms.21-0090>
- Zhang M, Sun X, Cheng J, Guo M (2022) Analysis and comparison of nutrition profiles of canine milk with bovine and caprine milk. *Foods* 11:472. <https://doi.org/10.3390/foods11030472>

## Publisher's Note

Springer Nature remains neutral with regard to jurisdictional claims in published maps and institutional affiliations.

Submit your manuscript to a SpringerOpen® journal and benefit from:

- Convenient online submission
- Rigorous peer review
- Open access: articles freely available online
- High visibility within the field
- Retaining the copyright to your article

---

Submit your next manuscript at ► [springeropen.com](https://www.springeropen.com)

---