

CASE REPORT

Open Access



Advanced gynecologic malignancy identified after acute stroke case report

Jack Jnani^{1*}

Abstract

Background Endometrial carcinosarcomas are rare and carry a very poor prognosis. They usually present with extensive lymphatic spread. An acute presentation of a stroke may reveal the underlying diagnosis.

Case presentation A woman in her 50s with no reported medical history presented to the emergency department as a code stroke. She was found during the evening by her sister leaving the bathroom disheveled. At that time, she was found to be mute, not following commands, with left gaze deviation and right hemiparesis. Computed tomography (CT) imaging showed an acute infarct in the left middle cerebral artery M2 branch or frontoparietal territory consistent with acute stroke. Upon further review, the sister states that she has had significant vaginal bleeding and never had menopause. On admission, she had significant anemia. CT of the abdomen and pelvis showed a large right adnexal mass, endometrial thickening, diffuse lymphadenopathy, omental nodularity, and a pulmonary nodule concerning for gynecologic malignancy with metastasis. Surgical pathology showed high grade endometrial carcinosarcoma. She was outside of the tPA window, and neurology determined her not to be a candidate for thrombectomy. She was managed medically with antiplatelet agents, high dose atorvastatin, and blood transfusions.

Conclusions Endometrial carcinosarcoma can present with severe anemia and irregular menstrual bleeding. In patients without routine gynecologic care, endometrial carcinosarcoma can go unnoticed and only be identified after workup for another condition such as acute stroke. Endometrial biopsy for diagnosis may be challenging in a patient with severe anemia. Alternatively, transvaginal ultrasonography with Doppler study and magnetic resonance imaging may be used to support the diagnosis. Furthermore, endometrial carcinosarcoma can complicate ischemic stroke management as it can present with bleeding and make it difficult to use anticoagulating agents.

Keywords Endometrial carcinosarcoma, Acute stroke, Infarct, Menopause, Bleeding, Anemia, Anticoagulation

Background

Endometrial carcinosarcomas are rare and carry a very poor prognosis. They usually present with extensive lymphatic spread. Treatment usually involves a combination of surgery, chemotherapy, immunotherapy, or radiation. Chemotherapy with carboplatin and paclitaxel is the preferred chemotherapy regimen (Crane 2022). Palliative therapy may be necessary in cases of extensive metastatic

spread. Malignancy does carry increased thromboembolism risk, though an acute stroke being the initial presentation of gynecologic malignancy is unique.

Case presentation

A woman in her 50s with no reported medical history (hasn't seen a physician in years) presented to the emergency department as a code stroke. She was found during the evening by her sister leaving the bathroom disheveled. At that time, she was found to be mute, not following commands, with left gaze deviation and right hemiparesis. She had no prior history of stroke. In addition, her sister also states that she has had significant vaginal bleeding for several years, with

*Correspondence:

Jack Jnani

jjnani@northwell.edu

¹ North Shore University Hospital, 300 Community Drive, Manhasset, NY 11030, USA

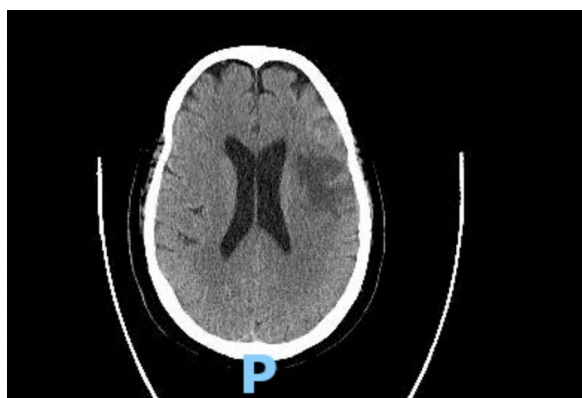


Fig. 1 Confluent transcortical hypoattenuation in the left frontal lobe due to acute infarction in the distribution of the left middle cerebral artery

episodes of lighter and heavier flow but never cessation of bleeding. She has not gone through menopause.

Investigations

CT imaging of the brain without contrast showed a moderate-sized acute infarct in the left frontoparietal convexity and left insula, within the left middle cerebral artery (M2) vascular territory (Fig. 1) consistent with an acute

stroke. CT angiography of the neck showed no hemodynamically significant carotid stenosis, 2.3 cm left posterolateral neck bilobed subcutaneous cystic focus with thin peripheral enhancement, destructive lytic lesion in the posterior aspect of the left fourth rib, and numerous enlarged cervical and mediastinal lymph nodes. CT of the chest, abdomen and pelvis with contrast showed a large 5.9×5.4 cm right adnexal mass (Fig. 2), endometrial thickening (Fig. 3), diffuse pelvic and abdominal lymphadenopathy, omental nodularity and masses, bilobed mass in mid-abdomen (Fig. 4), and a 6-mm right middle lobe lung nodule (Fig. 5) concerning for gynecologic malignancy with metastasis. Labs were significant for elevated Cancer Antigen 125 (CA-125) to 402 U/mL, Carcinoembryonic antigen (CEA) to 20.2 ng/mL, and Hemoglobin 5.6 g/dL on admission. Surgical pathology from an endometrial biopsy demonstrated Stage IVB endometrial carcinosarcoma (Figs. 6 & 7). The carcinosarcoma appeared to be arising in a background of a low grade endometrioid carcinoma (Fig. 8). An immunohistochemical stain for p53 was aberrant (overexpressed) in the high grade carcinosarcoma component (Fig. 9). An immunohistochemical stain for HER2 showed the tumor cells to be negative. The DNA MMR proteins MLH1, PMS2, MSH2, and MSH6 all showed retained expression. A beta-catenin showed membranous staining.

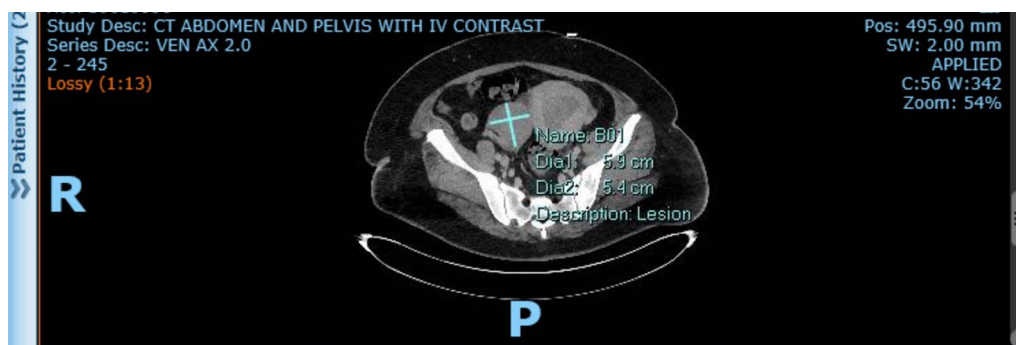


Fig. 2 5.9 centimeter (cm)×5.4 cm Right adnexal mass

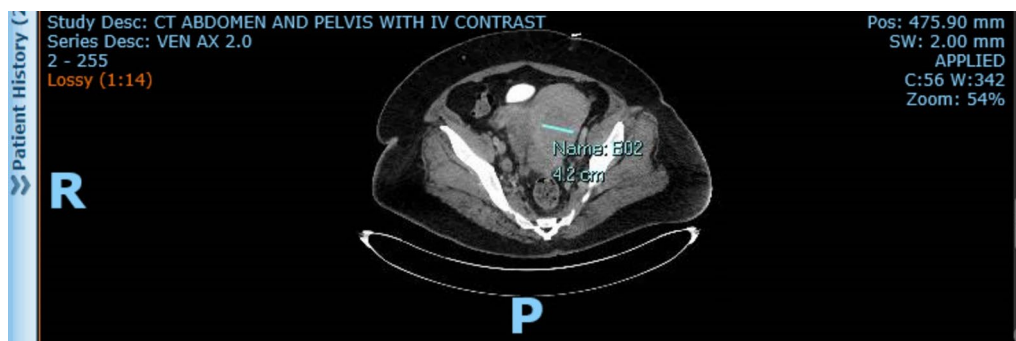


Fig. 3 Endometrial thickening up to 4.2 cm and heterogeneity

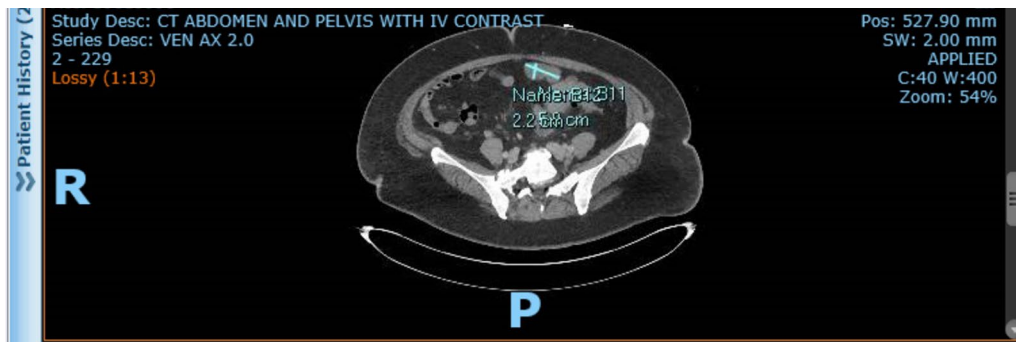


Fig. 4 Bilobed mass in mid-abdomen 5×2.2 cm

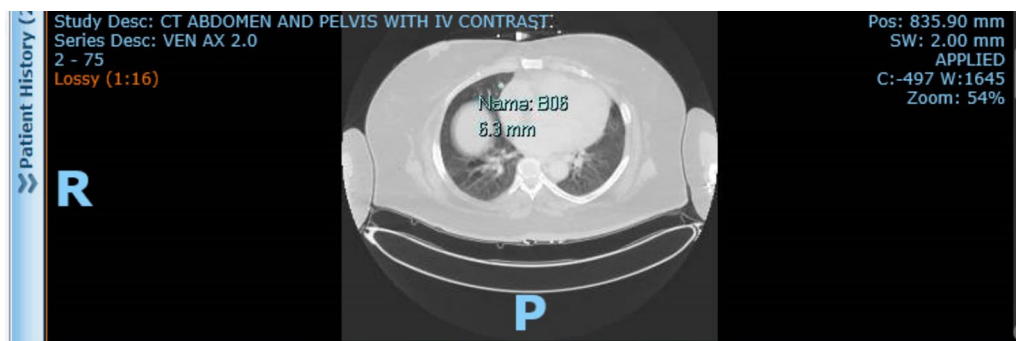


Fig. 5 6-millimeter (mm) right middle lobe lung nodule

Differential diagnosis

Given the above findings, and surgical pathology demonstrating endometrial carcinosarcoma, the most likely diagnosis was an acute stroke secondary to thromboembolism from underlying gynecologic malignancy.

Treatment

She was outside of the tPA window, and neurology determined her not to be a candidate for thrombectomy based on imaging. She was managed medically with antiplatelet

agents, high dose atorvastatin, and four units of blood transfusions for profound anemia.

Outcome and follow-up

She underwent palliative radiotherapy to reduce bleeding and was able to be put on reduced dose low molecular weight heparin. She was determined to be not a candidate for surgical therapy given metastatic disease. She was planned to go to rehabilitation and then follow up outpatient for systemic chemotherapy treatment.

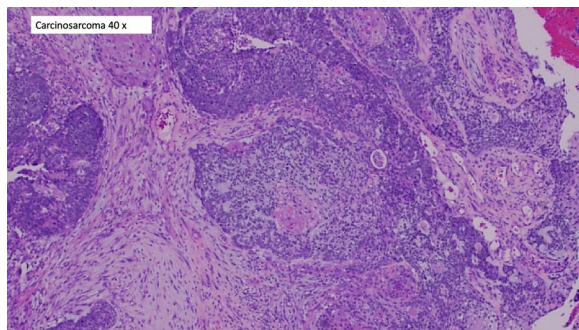


Fig. 6 Histopathology demonstrating Endometrial Carcinosarcoma at 40x magnification

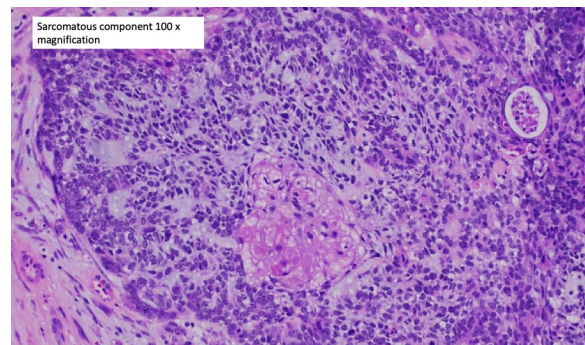


Fig. 7 Histopathology better illustrating the sarcomatous component at 100x magnification

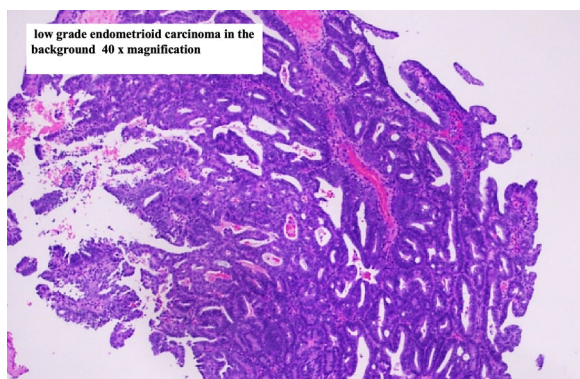


Fig. 8 Histopathology demonstrating low-grade endometrial carcinoma in the background

Discussion

Endometrial carcinosarcomas are rare aggressive tumors comprising less than 5% of uterine malignancies (Soror et al. 2021), and may be already metastatic on initial presentation. In the United States, the incidence is less than 2 per 100,000 women (Soror et al. 2021). The median age at diagnosis is 65 years old, and it is usually a disease of older post-menopausal females (Soror et al. 2021). African American women have a two-to-fourfold higher incidence of high-risk uterine cancer compared to Caucasian women (Abel et al. 2021).

Carcinosarcomas are comprised of both epithelial and mesenchymal components, visible on histological examination. They typically arise within the endometrial cavity. Risk factors for carcinosarcomas include obesity, pelvic

radiation, use of exogenous estrogen, Tamoxifen use, and nulliparity (Kord et al. 2020).

In a large study of 300 patients with carcinosarcomas, the most common symptoms included post-menopausal bleeding (82%), pelvic pain (13%) and vaginal discharge (10%) (Callister et al. 2001). Carcinosarcomas are aggressive tumors with a very poor prognosis.

Treatment should be patient specific. Surgery can be very useful. Total hysterectomy with bilateral salpingo-oophorectomy is usually mainstays of treatment. Interestingly, in a meta-analysis of high-risk histologic subtypes of endometrial cancer, minimally invasive surgery (for example, laparoscopic approach) did not significantly increase the risk for recurrence or mortality compared to an open surgical approach, and may be used (Kim et al. 2022). Lymphadenectomy is also very beneficial in limiting malignant tumor spread, though more recent literature supports the alternative approach of sentinel lymph node mapping (Crane 2022).

Combination chemotherapy with carboplatin and paclitaxel has demonstrated good effects in the literature and is considered the first-line regimen (Bogani et al. 2023). Though the literature is limited, there are some studies supporting the additional use of radiotherapy in high-risk endometrial cancer subtypes (Crane 2022; Cunha et al. 2018). Immunotherapy also remains a good option, especially in individuals who don't respond to chemotherapy. In addition, the Federal Drug Administration (FDA) approved the use of pembrolizumab and lenvatinib after disease progression on chemotherapy and immunotherapy in endometrial cancer subtypes with microsatellite instability (Bogani et al. 2023).

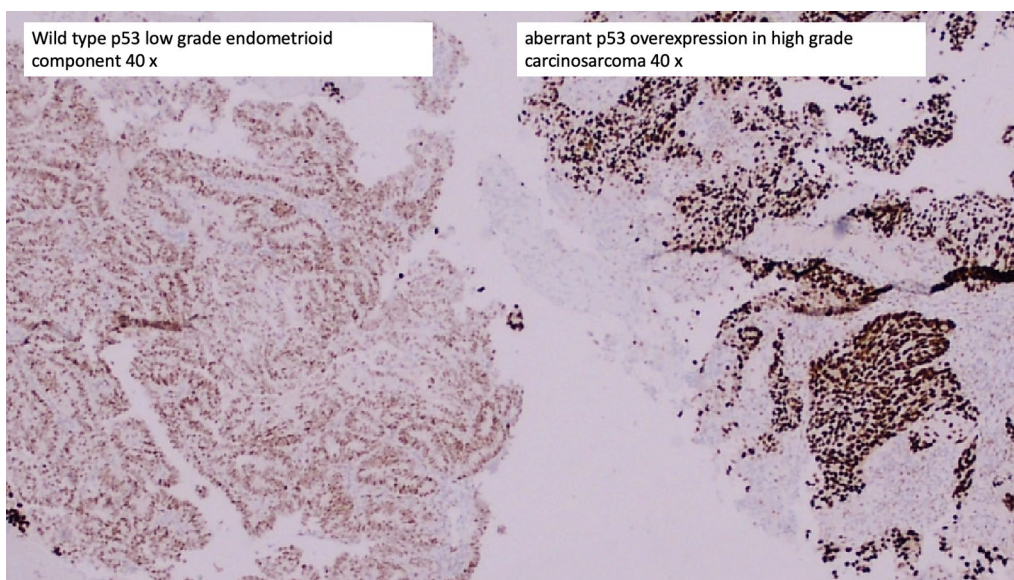


Fig. 9 Histopathology demonstrating p53 expression patterns in the low grade endometrioid versus high grade carcinosarcoma component

Post-operative imaging and surveillance of Cancer Antigen 125 (CA-125) levels can be used to monitor response to treatment. Additionally, molecular profiling has offered insight into actionable targets for personalized therapy and is guiding the future of oncologic therapy (Crane 2022).

Stage seems to be the most important prognostic factor, regardless of treatment. In a series of 121 patients with carcinosarcomas, five-year survival rates were 59% for Stage I/II, 22% for stage III, and 9% for Stage 4 disease (Gonzalez Bosquet et al. 2010). Carcinosarcomas can metastasize to the lungs (59%), peritoneum (44%), bones (17%), liver (15%), and brain (8%) (Gonzalez Bosquet et al. 2010). Palliative discussion is especially important in cases of advanced disease.

Given the poor prognosis, care should be taken in establishing the diagnosis early especially in more challenging presentations and creating an effective management plan.

Conclusions

- Endometrial carcinosarcoma, though commonly observed in post-menopausal females, can present before menopause as irregular menstruation, with episodes of heavier and lighter menstrual flow without cessation.
- In patients without routine gynecologic care, endometrial carcinosarcoma can go unnoticed and only identified once diffuse metastatic disease is present (stage IVB) and treatment is challenging, highlighting the need for regular gynecologic follow-up.
- Endometrial carcinosarcoma may be identified initially following an acute stroke and only uncovered after extensive neurological workup.
- For diagnosis, endometrial biopsy may be challenging in a patient with severe anemia. Alternatively, transvaginal ultrasonography with Doppler study and magnetic resonance imaging may be used to support the diagnosis.
- Endometrial carcinosarcoma can complicate ischemic stroke management as it can present with profound anemia and bleeding and make it difficult to use antiplatelet or anticoagulant agents commonly used in ischemic stroke management.

Abbreviations

CT	Computed tomography
tPA	Tissue plasminogen activator
CA-125	Cancer antigen 125
CEA	Carcinoembryonic antigen

Acknowledgements

We would like to acknowledge Dr. Sudarshana Roychoudhury and the histopathology team at North Shore University Hospital for assistance in obtaining the histopathology slides for this case.

Author contributions

JJ was responsible for the writing of the report, data acquisition, and analysis of data included in this report. All authors read and approved the manuscript prior to submission.

Funding

There were no sources of financial support for this case report from government or industry.

Availability of data and materials

All data generated or analyzed during this study are included in this published article [and its supplementary information files].

Declarations

Ethics approval and consent to participate

The following case report did not require ethics approval. Consent to participate was obtained from the patient and sister.

Consent for publication

Written informed consent was obtained from the patient included in this report, including permission for publication of data and clinical images.

Competing interests

The authors declare that they have no competing interests.

Received: 25 April 2023 Accepted: 20 June 2023

Published online: 11 July 2023

References

- Abel MK, Liao CI, Chan C et al (2021) Racial disparities in high-risk uterine cancer histologic subtypes: a United States cancer statistics study. *Gynecol Oncol* 161(2):470–476. <https://doi.org/10.1016/j.jgyno.2021.02.037>
- Bogani G, Ray-Coquard I, Concin N et al (2023) Endometrial carcinosarcoma. *Int J Gynecol Cancer* 33(2):147–174. <https://doi.org/10.1136/ijgc-2022-004073>
- Callister M, Jhingran A, Ramondetta L, Burke T, Eifel P (2001) Malignant mixed Müllerian tumors of the uterus: analysis of patterns of failure, prognostic factors, and treatment outcome. *Int J Radiat Oncol Biol Phys* 51(3):37–38
- Crane E (2022) Beyond serous: treatment options for rare endometrial cancers. *Curr Treat Options Oncol* 23(11):1590–1600. <https://doi.org/10.1007/s11864-022-01014-7>
- Gonzalez Bosquet J, Terstriep SA, Cliby WA et al (2010) The impact of multimodal therapy on survival for uterine carcinosarcomas. *Gynecol Oncol* 116(3):419–423. <https://doi.org/10.1016/j.jgyno.2009.10.053>
- Kim NR, Lee AJ, Yang EJ et al (2022) Minimally invasive surgery versus open surgery in high-risk histologic endometrial cancer patients: a meta-analysis. *Gynecol Oncol* 166(2):236–244. <https://doi.org/10.1016/j.jgyno.2022.06.004>

- Kord A, Rabiee B, Elbaz Younes I, Xie KL (2020) Uterine Carcinosarcoma: a case report and literature review. *Case Rep Obstet Gynecol* 2020:1–8
- Rodrigues da Cunha Colombo Bonadio R, Colombo Bonadio R, Gondim Meira Velame Azevedo R, Harada G et al (2018) Adjuvant carboplatin and paclitaxel chemotherapy followed by radiotherapy in high-risk endometrial cancer: a retrospective analysis. *J Glob Oncol* 4:1–8. <https://doi.org/10.1200/JGO.17.00146>
- Soror NN, Woredekal D, Hemrock L, Gibson G, Bennett R (2021) Uterine carcinosarcoma in a young female: case report and literature review. *Cureus* 13(1):e12642. <https://doi.org/10.7759/cureus.12642>

Publisher's Note

Springer Nature remains neutral with regard to jurisdictional claims in published maps and institutional affiliations.

Submit your manuscript to a SpringerOpen[®] journal and benefit from:

- ▶ Convenient online submission
- ▶ Rigorous peer review
- ▶ Open access: articles freely available online
- ▶ High visibility within the field
- ▶ Retaining the copyright to your article

Submit your next manuscript at ▶ [springeropen.com](https://www.springeropen.com)
