


CASE REPORT

Open Access



# Abscess formation caused by a foreign body reaction to a poly-D, L-lactic acid (PDLLA) absorbable plate for zygomaticomaxillary complex (ZMC) fracture

Fumikazu Tamura, Kaoru Sasaki\* , Junya Oshima, Hironao Hanihara, Risa Myojo, Yoichiro Shibuya, Masahiro Sasaki, Yukiko Aihara and Mitsuru Sekido

## Abstract

**Background:** The poly-D, L-lactic acid absorbable plate does not contain poly L-lactic acid, which is the main factor in foreign body reactions; therefore, with use of this plate, a foreign body reaction is unlikely. In fact, few reports have been published on removal of a poly-D, L-lactic acid absorbable plate owing to a foreign body reaction.

**Case presentation:** We report a case of abscess formation that led finally to the removal of a poly-D, L-lactic acid absorbable plate. A 45-years-old man with a left zygomaticomaxillary complex fracture sustained during a fall underwent open reduction using the poly-D, L-lactic acid absorbable plate. Fourteen months after the operation, he was admitted to our hospital with swelling and redness of the left lateral part of the upper eyelid. Upon incision of the swelling, we found a large amount of purulent drainage and the plate in broken fragments and removed as many of the fragments as possible. The swelling was improved after drainage of the incision twice and use of antibiotics, and the bacterial culture results were negative. No recurrence or aggravation was observed after the drainage.

**Conclusions:** We suspected sterile abscess formation secondary to a foreign body reaction to the poly-D, L-lactic acid absorbable plate. Given that the poly-D, L-lactic acid absorbable plate is absorbed over a period of more than 1 year postoperatively, long-term follow-up of injuries treated using the plate may be required. Furthermore, surgical intervention, such as drainage or removal, should be considered if the foreign body reaction symptoms are severe.

**Keywords:** Poly-D, L-lactic acid absorbable plate, PDLLA, Foreign body reaction, Sterile abscess

## Background

When it was first used, the absorbable plate for facial bone fractures was composed mainly of poly L-lactic acid (PLLA). However, delayed foreign body reactions during the absorption process have been pointed out as a defect. Since then, PLLA has been mixed with polyglycolic acid (PGA) or hydroxyapatite (HA), and other materials such as poly-D, L-lactic acid (PDLLA) have been used to

cope with foreign body reactions. In particular, PDLLA is amorphous and therefore considered to be unlikely to cause a foreign body reaction. Indeed, few reports have been published on the removal of a PDLLA absorbable plate owing to a foreign body reaction. We report a case of sterile abscess at the fixation site in which a PDLLA absorbable plate was used for a zygomaticomaxillary complex (ZMC) fracture and the subsequent removal of this plate.

\*Correspondence: [sasakikaoru32@hotmail.com](mailto:sasakikaoru32@hotmail.com)

Department of Plastic and Reconstructive Surgery, University of Tsukuba, Tsukuba, Ibaraki 305-8576, Japan

### Case presentation

A 45-years-old man sustained a left ZMC fracture after a fall from a height. Hypesthesia in the area of the second branch of the trigeminal nerve, disturbance of mouth opening, and malocclusion were observed. No ocular motility disorder or diplopia was observed (Fig. 1). Computed tomography (CT) showed fracture lines on the anterior and posterior walls of each of the left maxillary sinus, infraorbital wall, and the zygomatic arch, and the zygomatic body was deviated laterally downward (Fig. 2). On the 11th day after the injury, open reduction in the ZMC fracture was performed under general anesthesia.

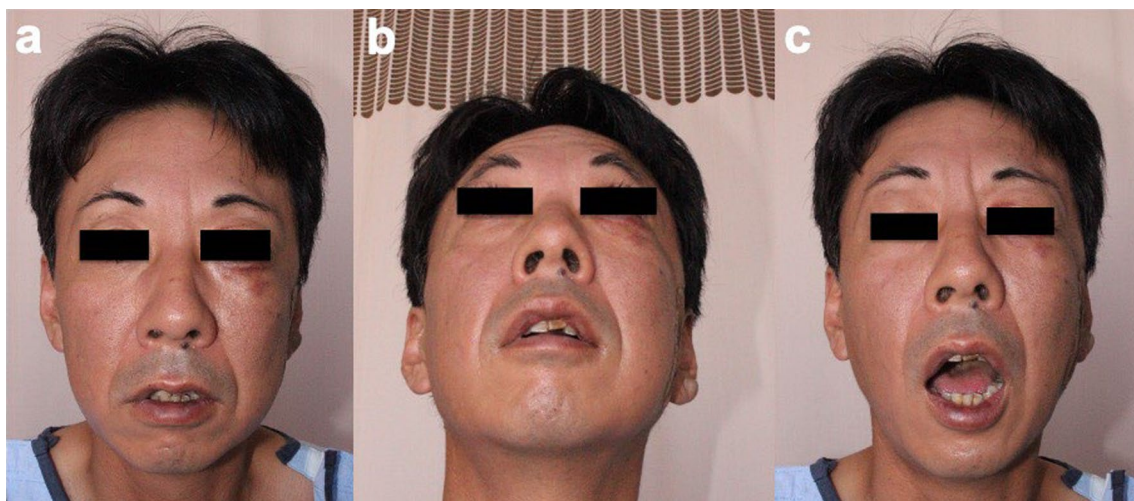
Three incisions were made in the upper oral vestibule, the lateral side of the tail hair, and the infraorbital margin to identify the fracture line. Both the frontal zygomatic suture and the infraorbital margin were fixed with a straight 4-hole, a 1.0 mm PDLA absorbable plate, and four 5 mm pins (Sonic Weld Rx<sup>®</sup>, KLS Martin) (Fig. 3). The subzygomatic ridge was not fixed because the dislocation was less.

The postoperative course was uneventful, but 14 months after the operation, the patient was admitted to our hospital because of swelling and redness of the left lateral part of the upper eyelid. The redness and swelling were 60 × 30 mm in diameter. The infraorbital margin was slightly distended without redness or swelling. The left lateral part of the upper eyelid was soft, and abscess formation inside was suspected. Therefore, a confirmatory incision was performed, and purulent drainage and a fractured plate were observed (Fig. 4). The lumen was washed out as much as possible, and the bacterial culture results were negative. Thus, the swelling was

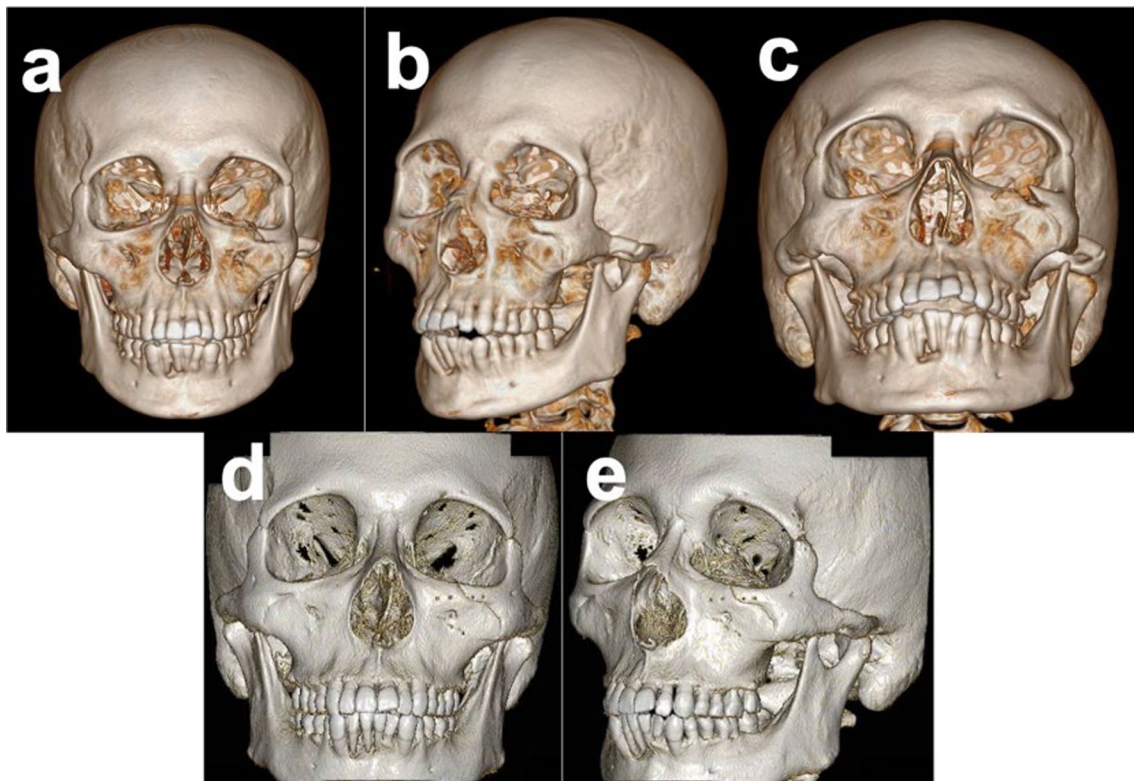
thought to be sterile abscess. Fourteen days later, washing drainage was carried out again because the inflammation remained. Antibiotics were administered for 14 days from the first day of the return visit. The redness and swelling were improved 21 days after the last drainage. No clear recurrence had occurred 16 months after the operation (2 months after the last drainage) (Fig. 5). At that time, slight swelling was also observed in the infraorbital region, but no accompanying symptoms such as redness were observed, and follow-up was planned. Finally, the swelling of the left lateral part of the upper eyelid had disappeared 24 months postoperatively (10 months after the last drainage). Mild bulging of the infraorbital margin remained, but no exacerbation was noted (Fig. 5).

### Discussion

Absorbable plates are widely used for facial fractures. The main advantage of absorbable plates is that removal is unnecessary because they are completely decomposed by metabolism. The conventional absorbable plate is composed of polymers containing mainly PLLA. PLLA is semicrystalline and highly hydrophobic and requires 5–6 years to degrade (Xue et al. 2014; Eppley et al. 2004). The degradation of an absorbable plate is said to consist of two steps: The first step is hydrolysis, which breaks the chemical bonds of the polymer into a low molecular weight polymer. In the second step, these substances are further degraded and metabolized to CO<sub>2</sub> and H<sub>2</sub>O (Jeon et al. 2016). During this degradation, a foreign body reaction may occur, causing, for example, redness and swelling. The crystallinity of the constituent substances is considered the most important factor in the foreign



**Fig. 1** **a** He felt hypesthesia in the area of malocclusion of the second branch of the trigeminal nerve. **b** His left cheek was more deviated downward than the right cheek. **c** He had difficulty opening his mouth



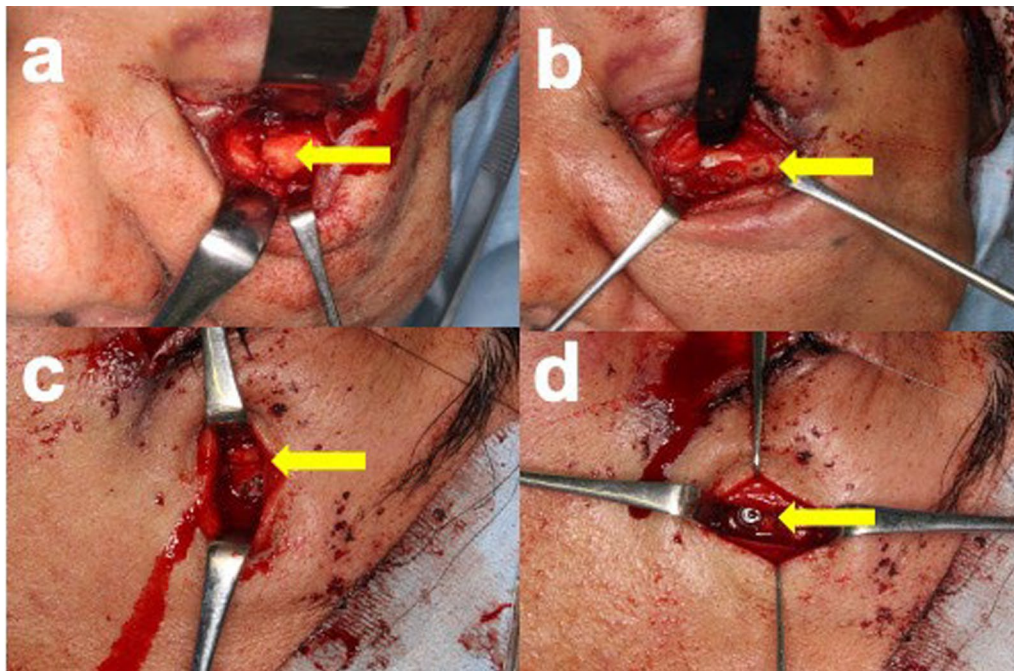
**Fig. 2** **a** Frontal view (fractures of the anterior and posterior walls of the left maxillary sinus, the infraorbital wall, and the frontal zygomatic suture). **b** Oblique view (The zygomatic arch also broken). **c** Tilt view (The zygomatic body was deviated laterally downward). **d** Frontal view 6 months postoperatively (The bones were successfully reduced). **e** Oblique view 6 months postoperatively

body reaction. The decomposition exceeds the permissible level of metabolism, and the crystalline substance as an intermediate product remains for a long time. This is main factor in the foreign body reaction. (Kim and Lee 2019).

The PDLLA absorbable plate is a new plate composed of PDLLA alone. Unlike PLLA, PDLLA is an amorphous substance, and therefore, no crystalline substance is formed as an intermediate product. In addition, PDLLA is absorbed in 72 weeks (Heidemann et al. 2001), so a foreign body reaction is less likely to occur than if a conventional absorbable plate is used. The foreign body reaction of the PDLLA absorbable plate was reported to be transient swelling, as it was for other absorbable plates (Aldanaa et al. 2011; Reichwein et al. 2009; Yukari et al. 2020; Itaru et al. 2020). However, as yet few reports have been published of a foreign body reaction requiring surgery: in one report, only a foreign body granuloma was formed in seven cases (Jeon et al. 2016) and in two other reports, the swelling remained without spontaneous regression in two

cases (Hitoshi et al. 2019; Doh et al. 2018). Although the PDLLA absorbable plate is a new material with different features from those of the conventional product, further case study is necessary on the progress and frequency of the foreign body reaction in future.

In our case, the upper eyelid was highly swollen with redness and purulent drainage; thus, we considered the presence of severe inflammation. Plate fragments were observed at the wound, suggesting that degradation and absorption of the plate were stagnant. Furthermore, the bacterial culture results were negative, suggesting that the foreign body reaction accompanied by delayed degradation and absorption of the plates was the cause. The degradation process of an absorbable plates is histologically divided into five stages: protein adsorption, acute inflammation, chronic inflammation, foreign body giant cell formation, and fibrosis of the plate fragments, in which the fibrosis of the fragments is said to promote the foreign body reaction (Doh et al. 2018; Anderson et al. 2008). We thought that, because the plate was not completely decomposed, the inflammatory response



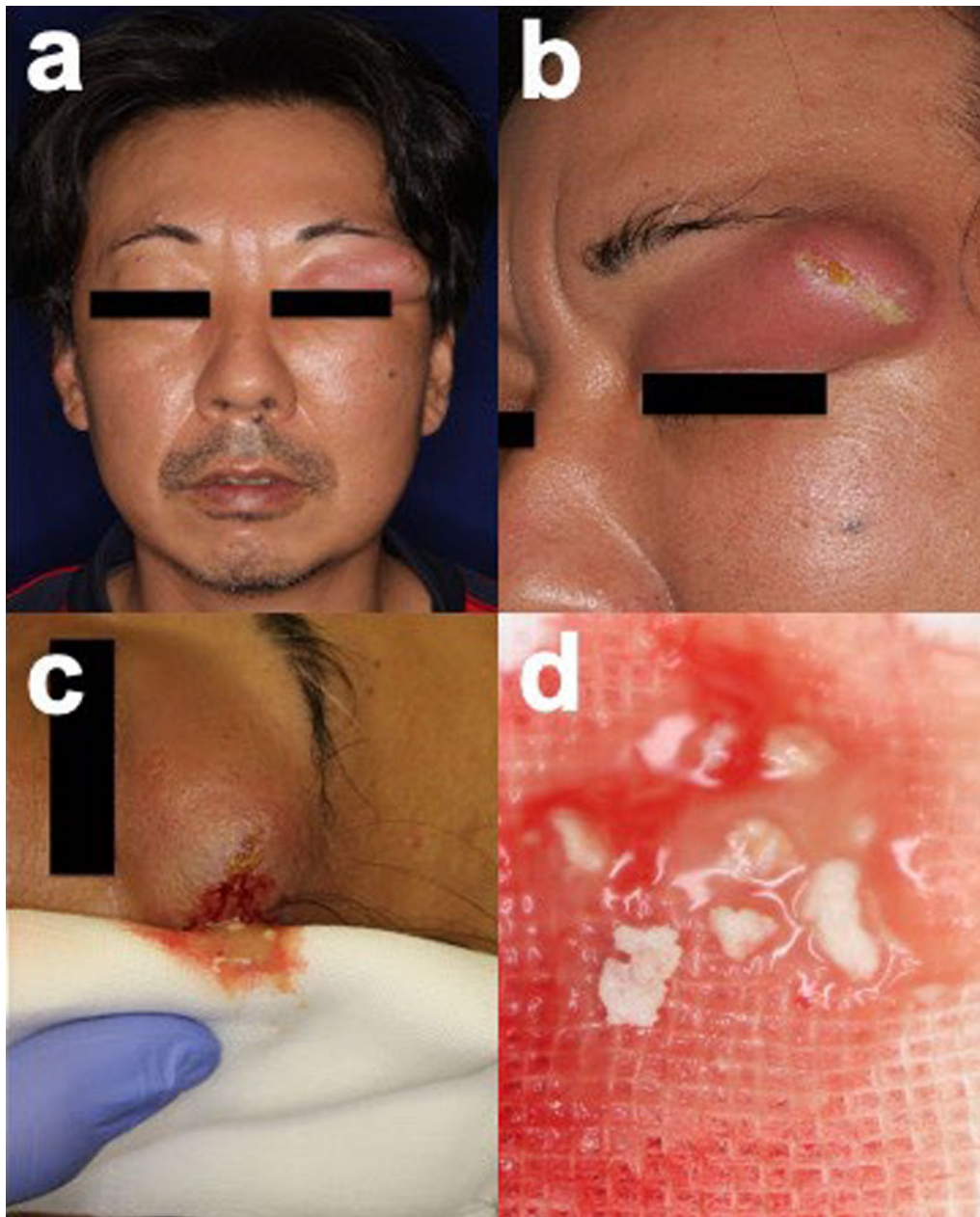
**Fig. 3** **a** Fracture at the infraorbital margin. **b** After plating at the infraorbital margin using a straight 4-hole, a 1.0 mm plate and four 5 mm pins were inserted. **c** Fracture at the frontal zygomatic suture. **d** After plating at the frontal zygomatic suture using a straight 4-hole, a 1.0 mm plate and four 5 mm pins were inserted

to the fragments was prolonged and spread to the surrounding tissues, resulting in the formation of a sterile abscess. Although the bacterial culture results were negative, the possibility that bacterial infection caused the inflammation cannot be completely ruled out.

In addition to the degree of crystallinity, factors that cause a foreign body reaction to an absorbable plate include the size, shape, and arrangement of the plate; the dead space around the indwelling plate; the thickness of the normal tissue covering the plate; and the proximity to the skin incision (Xue et al. 2014; Rha et al. 2015; Kim et al. 2018). In our case, the foreign body reaction was stronger at the frontozygomatic suture than at the infraorbital margin. Given aseptic inflammation rather than infection, the difference in the degree of the foreign body response may be related to periosteal repair after bone fixation. The periosteum at the infraorbital margin could be repaired after bone reduction, but that at the zygomaticofrontal suture could not be repaired because there was not enough periosteum to cover the thickness of the plate. In other words, whether hydrolysis of the plate placed on the bone surface occurs inside or outside the periosteum was important, and the periosteum possibly suppressed the spread of inflammation to the circumference.

Therefore, periosteal repair sufficient to cover the plate was considered to be important for reducing the foreign body reaction to the plate. With regard to plate fixing, we should select a site that allows for not only bone fixation but also sufficient periosteum to cover the plate.

The foreign body reaction caused by an absorbable plate is often transient. However, if the abscess is formed with extensive and intense inflammation, as in our case, surgical intervention should be considered for distinguishing a foreign body reaction from a bacterial abscess. Although no clear criteria exist for the indication of surgical intervention for foreign body reactions, it has been suggested that surgical removal should be performed for swelling that remains 2 years after surgery because of the possibility of subsequent bone resorption (Mackool et al. 2006). PDLA absorbable plates are relatively new products, and their hydrolysis progresses over a period of more than 1 year. Therefore, long-term follow-up for 1 year or more after surgery is necessary to confirm the presence and extent of a foreign body reactions. Furthermore, surgical intervention, such as drainage or removal, should be considered if the foreign body reaction symptoms are severe.

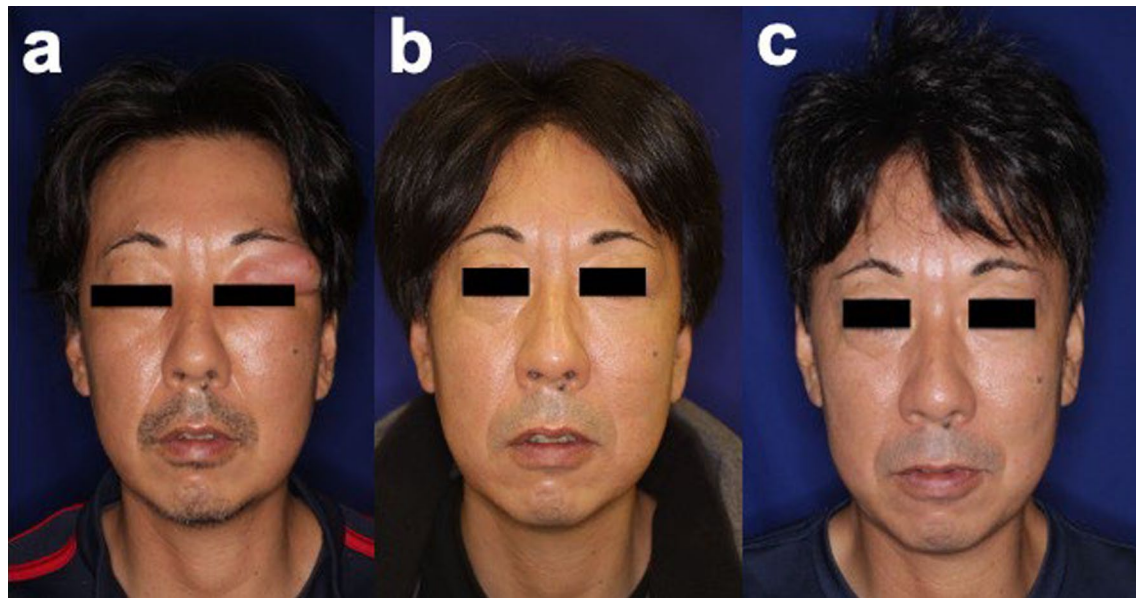


**Fig. 4** **a** Redness and swelling of 60 × 30 mm in diameter in the upper eyelid. **b** The swelling was soft, so a bacterial infection and abscess were suspected. **c** After confirmatory incision, purulent drainage was observed. **d** The purulent drainage contained plate fragments

### Conclusions

The poly-D, L-lactic acid absorbable plate is absorbed over a period of 1 postoperatively, necessitating a long-term follow-up of 1 year or longer. In addition,

although the foreign body reaction is often transient, surgical intervention, such as drainage or removal, should be considered if the symptoms of the foreign body reaction are severe.



**Fig. 5** **a** 14 months after the operation (first return to our hospital). **b** 16 months after the operation (2 months after the last drainage): the swelling and redness had improved. **c** 24 months postoperatively (10 months after the last drainage): the swelling had disappeared

#### Abbreviations

ZMC: Zygomaticomaxillary complex; PLLA: Poly L-lactic acid; PGA: Polyglycolic acid; HA: Hydroxyapatite; PDLLA: Poly-D, L-lactic acid; CT: Computed tomography.

#### Acknowledgments

The authors would like to express their deepest appreciation to F. Miyamasu, Medical English Communications Center, University of Tsukuba.

#### Author contributions

FT is the first author of the paper. KS and JO contributed to the case report as FT's supervising physician. HH and RM attended the patient's surgery. YS, MS, and YA gave me suggestions for foreign body reaction findings and paper searches. MS oversaw the preparation of case reports as a professor. All authors read and approved the final manuscript.

#### Funding

We declare that no funds, grants, or other support were received during the preparation of this manuscript.

#### Availability of data and materials

Not applicable.

#### Declarations

##### Ethics approval and consent to participate

Ethics approval is not required by the Ethics Committee of the University of Tsukuba Hospital.

##### Consent for publication

The patient provided written informed consent for publication of his photographs.

##### Competing interests

The authors declare that they have no competing interests.

Received: 22 July 2022 Accepted: 12 December 2022

Published online: 19 December 2022

#### References

- Aldanaa PR, Wieder K, Postlethwait RA, James HE, Steinberg B (2011) Ultrasound-aided fixation of biodegradable implants in pediatric craniofacial surgery. *Pediatr Neurosurg* 47:349–353
- Anderson JM, Rodriguez A, Chang DT (2008) Foreign body reaction to biomaterials. *Semin Immunol* 20:86–100
- Doh G, Bahk S, Hong KY, Lim S, Han KM, Eo S (2018) Delayed formation of sterile abscess after zygomaticomaxillary complex fracture treatment with bioabsorbable plates. *Arch Craniofac Surg* 19:143–147
- Eppley BL, Morales L, Wood R, Pensler J, Goldstein J, Havlik RJ, Habal M, Losken A, Williams JK, Burstein F, Rozzelle AA, Sadove AM (2004) Resorbable PLLA-PGA plate and screw fixation in pediatric craniofacial surgery: clinical experience in 1883 patients. *Plast Reconstr Surg* 114:850–856
- Heidemann W, Jeschkeit S, Ruffieux K, Fischer JH, Wagner M, Krüger G, Wintermantel E, Gerlach KL (2001) Degradation of poly(D, L)lactide implants with or without addition of calcium-phosphates in vivo. *Biomaterials* 22:2371–2381
- Hitoshi N, Mari G, Kenta M, Seiko N (2019) Postoperative complications due to absorbable osteosynthesis device in maxillo-facial bone fracture. *J Jpn PRS* 39:446–451
- Itaru E, Hiroyuki T, Yasuyo K, Makoto S (2020) The clinical experience of ultrasound-aided fixation using an absorbable plate system in the treatment of zygomatic fractures. *J Jpn PRS* 40:407–413
- Jeon HB, Kang DH, Gu JH, Oh SA (2016) Delayed foreign body reaction caused by bioabsorbable plates used for maxillofacial fractures. *Arch Plast Surg* 43:40–45
- Kim TH, Kang SJ, Sun H (2018) Delayed degradation according to the location of fixation with using an absorbable plate. *Arch Craniofac Surg* 19:114–119
- Kim YM, Lee JH (2019) Clinical courses and degradation patterns of absorbable plates in facial bone fracture patients. *Arch Craniofac Surg* 20:297–303
- Mackool R, Yim J, McCarthy JG (2006) Delayed degradation in a resorbable plating system. *J Craniofac Surg* 17:194–197
- Reichwein A, Schicho K, Moser D, Seemann R, Poeschl P, Baumann A, Ewers R (2009) Clinical experiences with resorbable ultrasonic-guided, angle-stable osteosynthesis in the panfacial region. *J Oral Maxillofac Surg* 67:1211–1217

- Rha EY, Paik H, Byeon JH (2015) Bioabsorbable plates and screws fixation in mandible fractures: clinical retrospective research duaring a 10-year period. *Ann Plast Surg* 74:432–436
- Xue AS, Koshy JC, Weathers WM, Wolfswinkel EM, Kaufman Y, Sharabi SE, Brown RH, Hicks MJ, Hollier LH (2014) Local foreign-body reaction to commercial biodegradable implants: an in vivo animal study. *Craniomaxillofac Trauma Reconstr* 7:27–34
- Yukari N, Yoshiaki S, Tomoru M, Kazunari Y, Kazuo K (2020) Complications of crani-ofacial surgery using the ultrasonic-assisted pinned resorbable system: a prospective report with a miimum follow-up of 30 months. *J Plast Reconstr Aesthet Surg* 73:586–589

### **Publisher's Note**

Springer Nature remains neutral with regard to jurisdictional claims in published maps and institutional affiliations.